

Organization of the Body

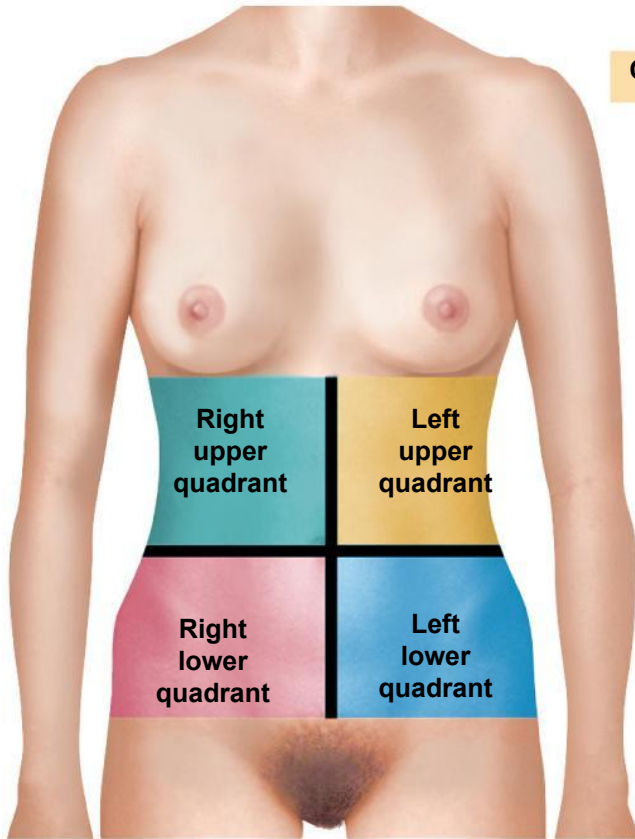


**Al-Farabi Kazakh
National
University
Higher School of
Medicine**

Body Regions

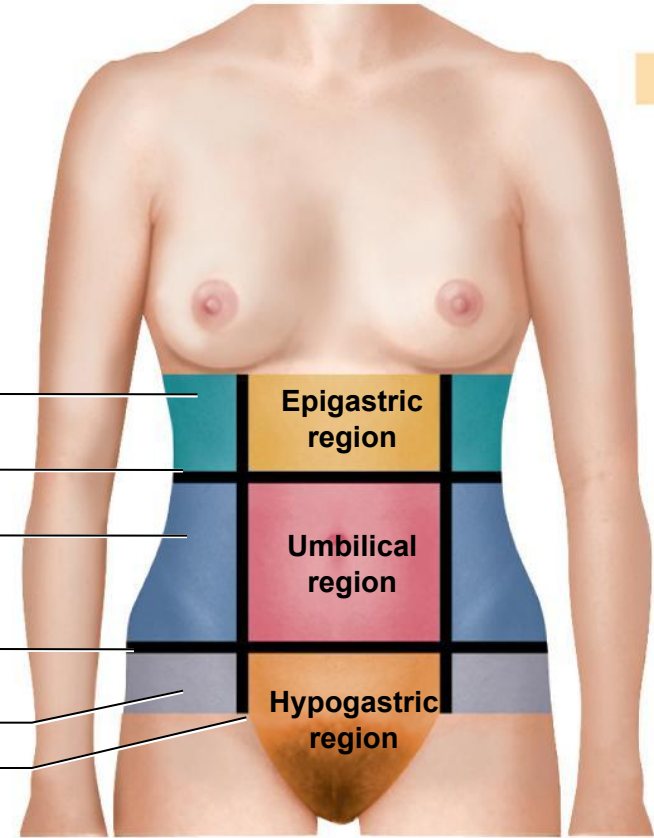
- **Axial region = head, neck, & trunk**
 - thoracic region = trunk above diaphragm
 - abdominal region = trunk below diaphragm
 - divided into quadrants
 - divided into nine regions by tic-tac-toe grid
- **Appendicular region = upper & lower limbs**
 - upper limb
 - arm (brachial region), forearm (antebrachial region), wrist (carpal region), hand (manual region), fingers (digits)
 - lower limb
 - thigh (femoral region), leg (crural region), ankle (tarsal region), foot (pedal region), toes (digits)

Abdominal Quadrants and Regions



Quadrants

(a)



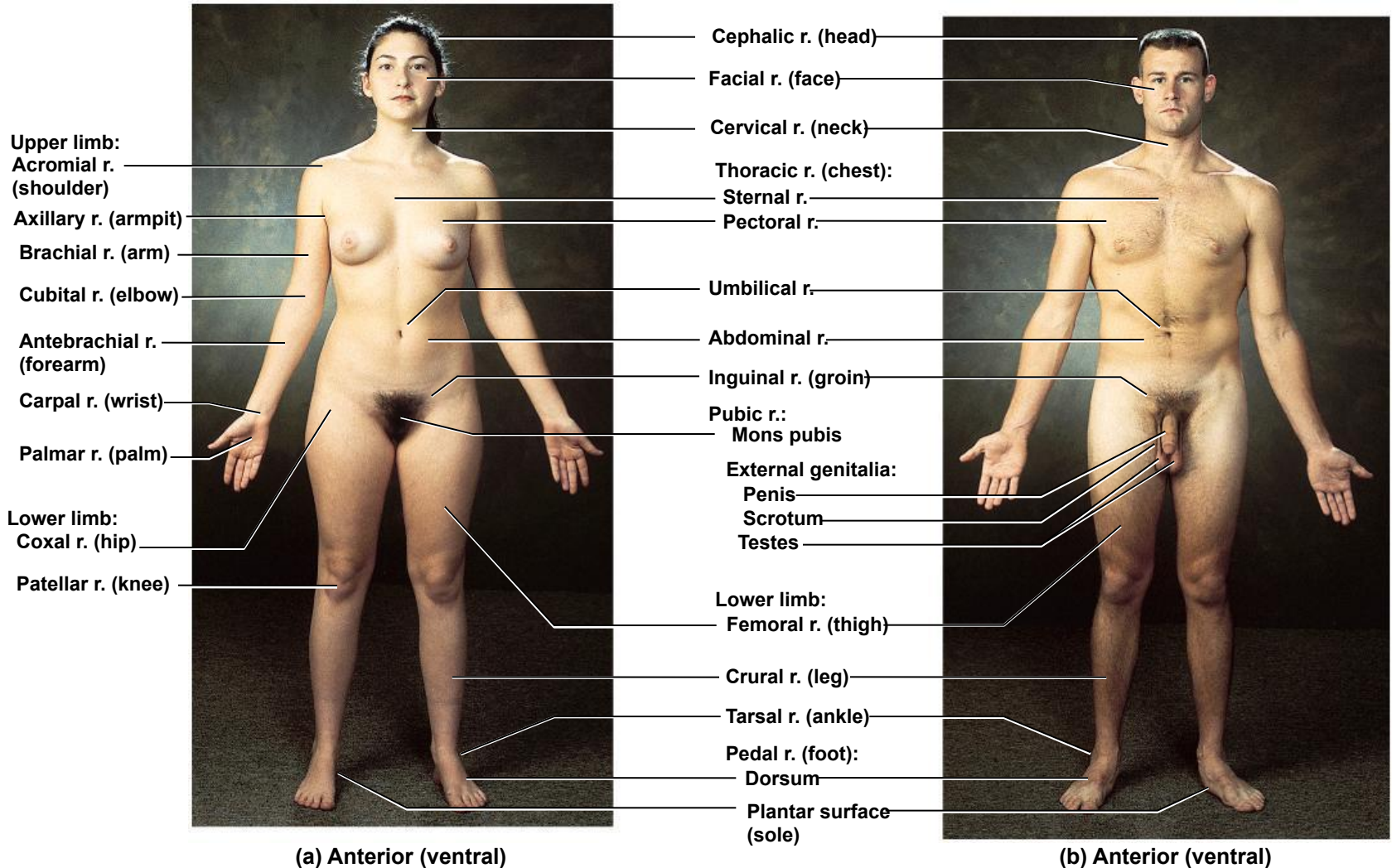
Regions

(c)

Figure A.6

Anatomical Terminology (ventral)

Anatomy & Physiology: The Unity of Form and Function McGraw-Hill Education; 8th Edition

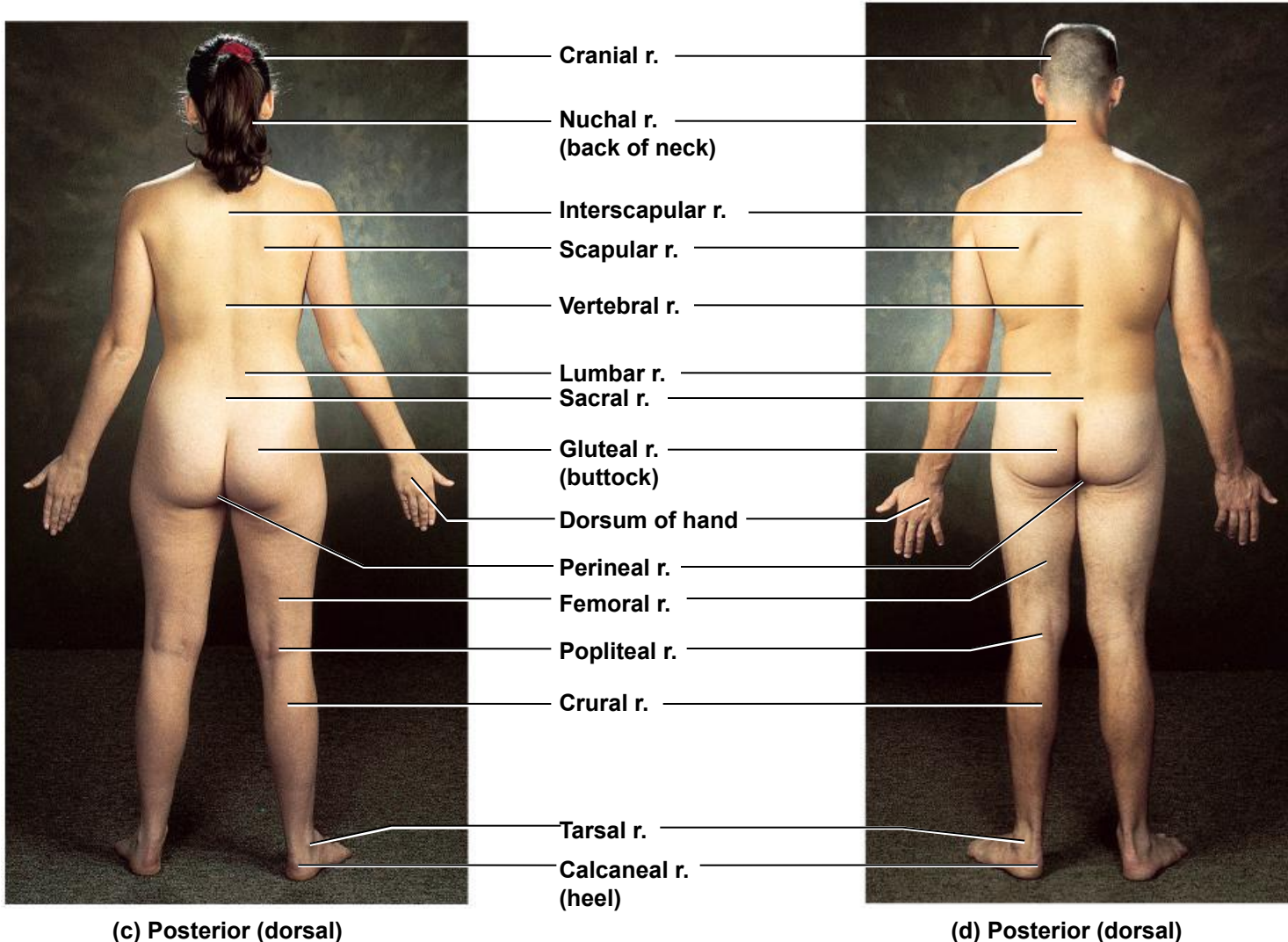


© McGraw-Hill Companies/Joe DeGrandis, photographer

Figure A.5

Anatomical Terminology (dorsal)

Anatomy & Physiology: The Unity of Form and Function McGraw-Hill Education; 8th Edition

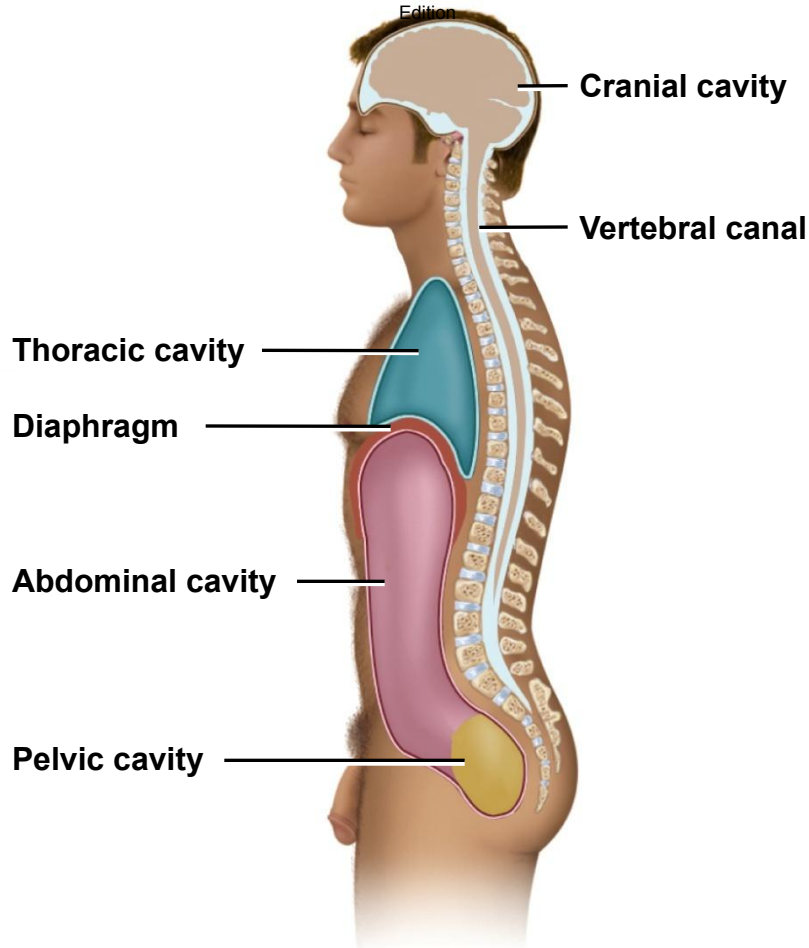


© McGraw-Hill Companies/Joe DeGrandis, photographer

Figure A.5

Body Cavities and Membranes

Anatomy & Physiology: The Unity of Form and Function McGraw-Hill Education; 8th Edition



(a) Left lateral view

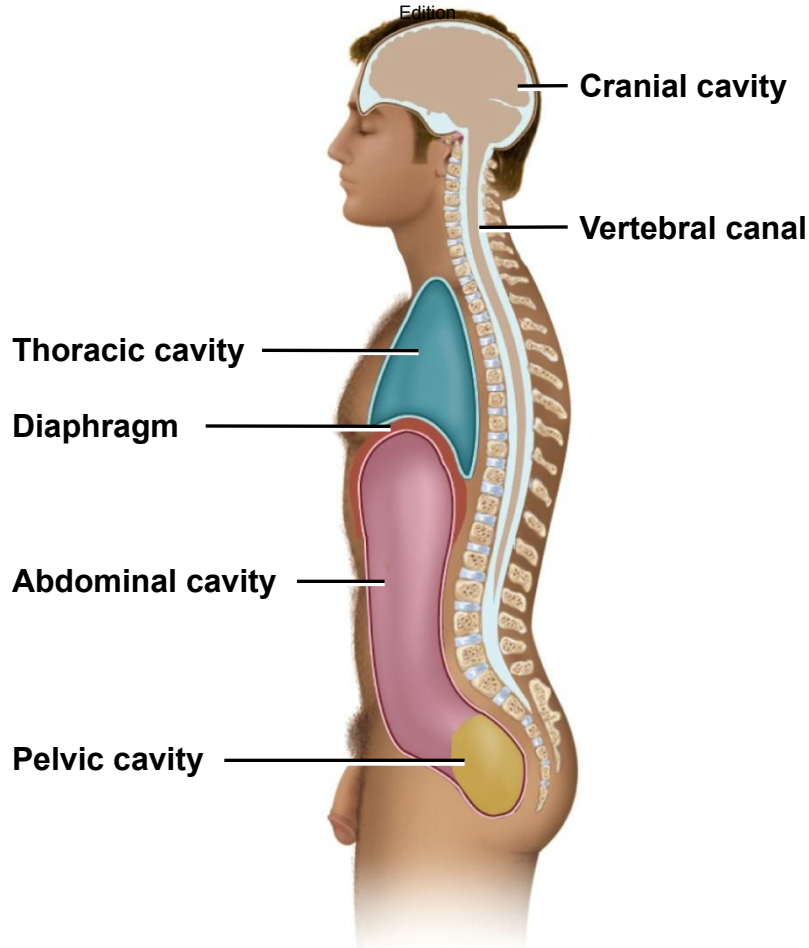
Figure A.7

Major body cavities

- cranial cavity
 - vertebral canal
 - meninges
 - thoracic cavity
 - abdominopelvic cavity
 - abdominal cavity
 - pelvic cavity
-
- Lined by **serous membranes**

Cranial Cavity & Vertebral Canal

Anatomy & Physiology: The Unity of Form and Function McGraw-Hill Education; 8th Edition



(a) Left lateral view

Figure A.7

- **cranial cavity**
 - contains brain
 - lined with meninges

- **vertebral canal**
 - contains the spinal cord
 - lined with meninges

Thoracic Cavity

- **Mediastinum** - region between lungs

- heart, major blood vessels, esophagus, trachea, & thymus

Anatomy & Physiology: The Unity of Form and Function McGraw-Hill Education; 8th Edition

- **Pericardium** – around heart

- visceral pericardium
- parietal pericardium
- pericardial cavity
- pericardial fluid

- **Pleura** – around lungs

- visceral pleura
- parietal pleura
- pericardial cavity
- pericardial fluid

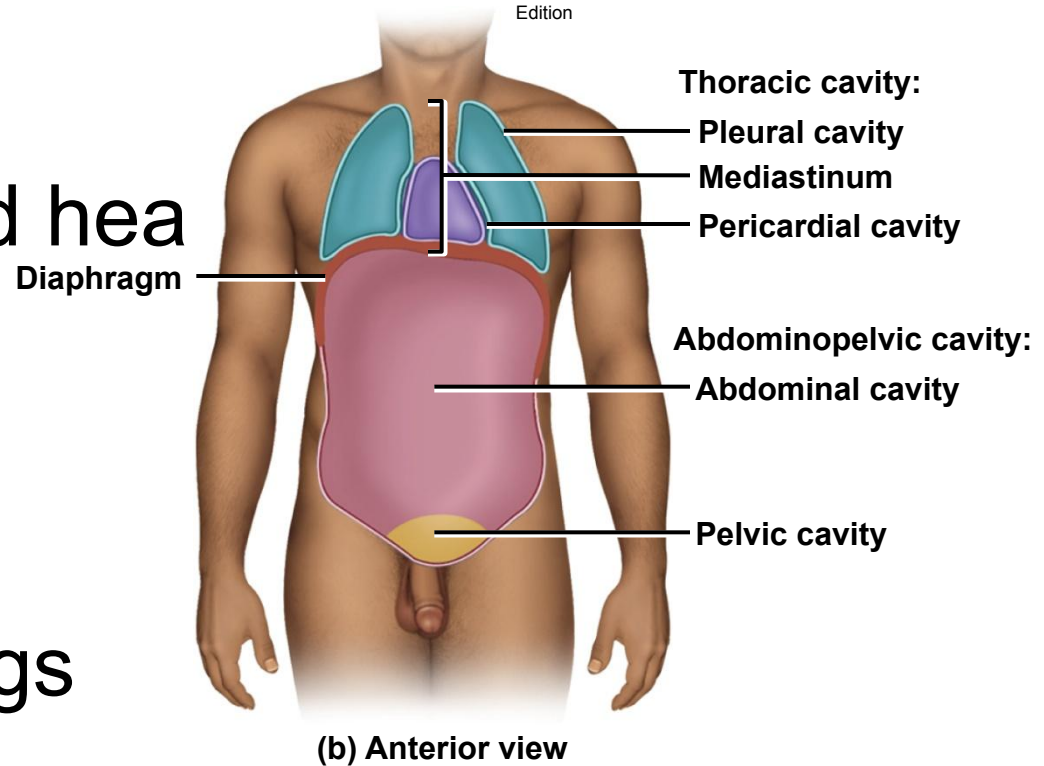
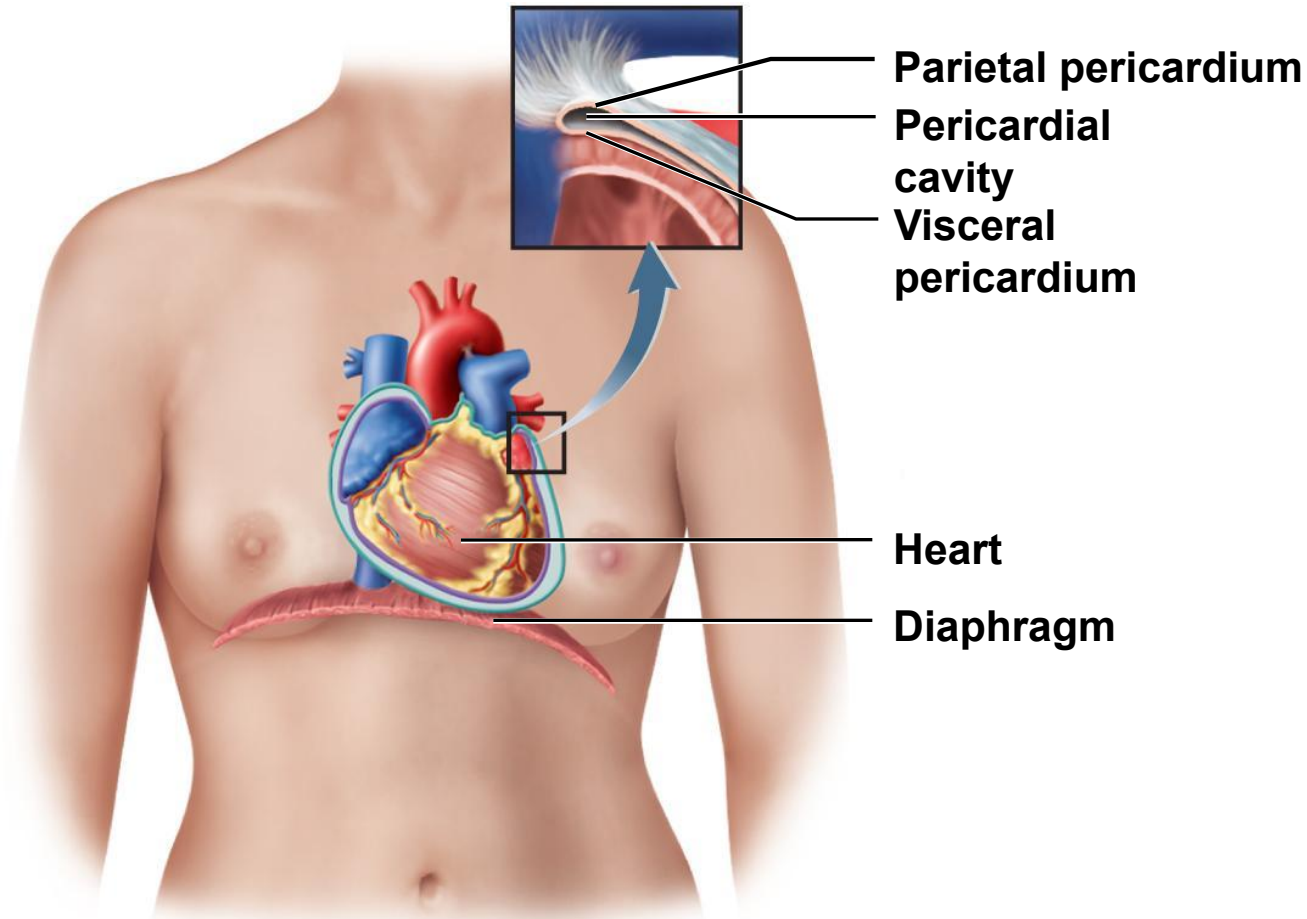


Figure A.7

Pericardial Membranes

Anatomy & Physiology: The Unity of Form and Function McGraw-Hill Education; 8th Edition

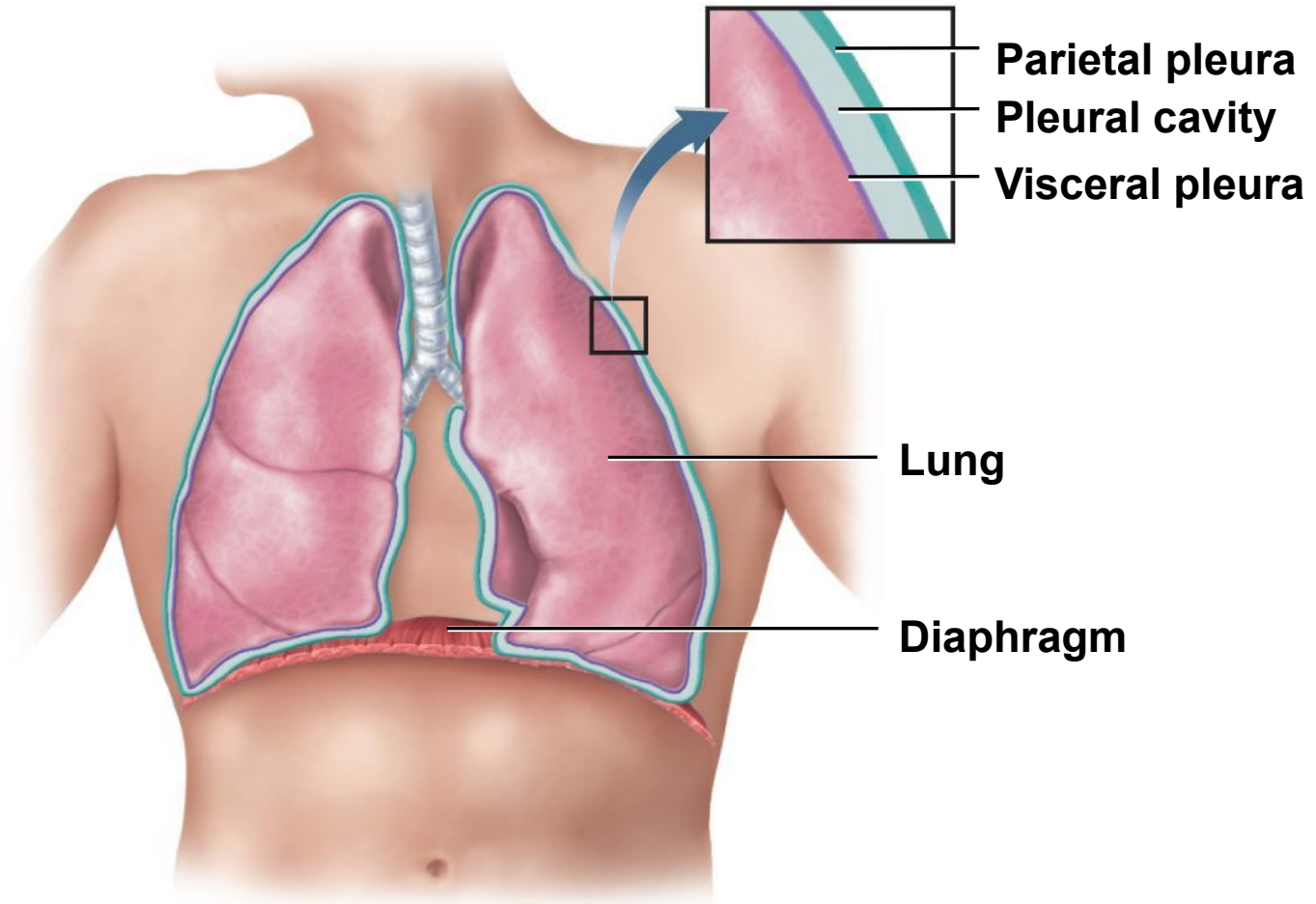


(a) Pericardium

Figure A.8a

Pleural Membranes

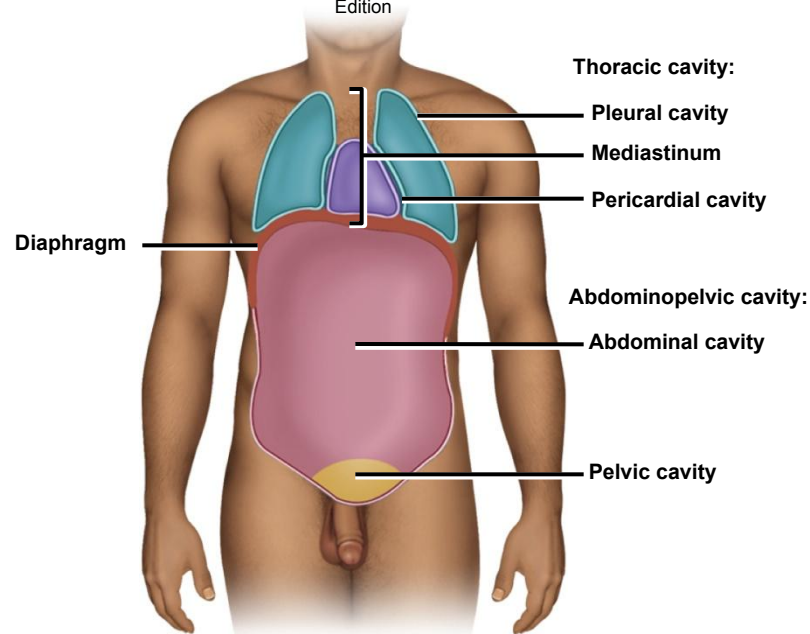
Anatomy & Physiology: The Unity of Form and Function McGraw-Hill Education; 8th Edition



(b) Pleurae
Figure A.8b

Abdominopelvic Cavity

Anatomy & Physiology: The Unity of Form and Function McGraw-Hill Education; 8th Edition



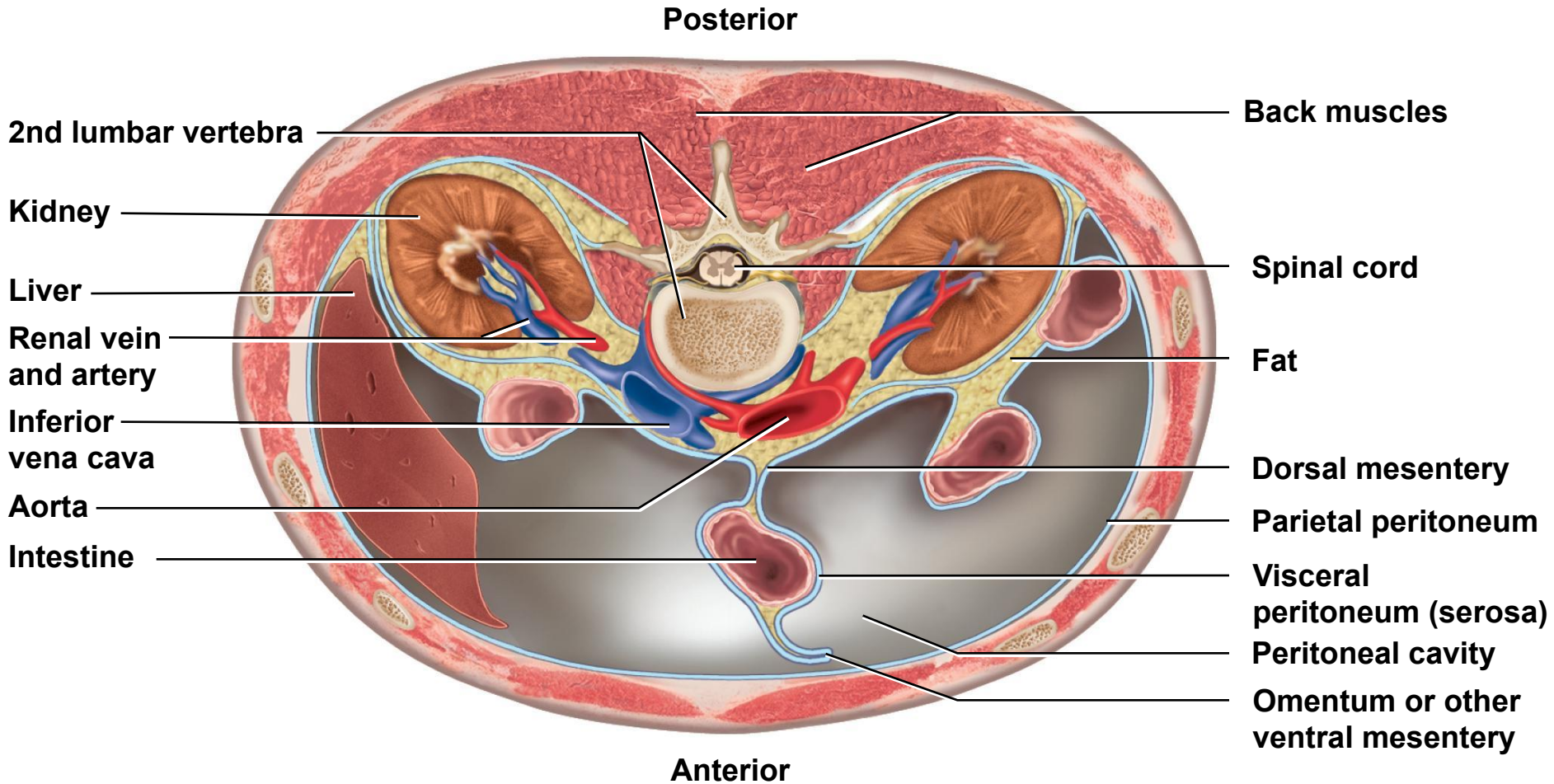
(b) Anterior view

Figure A.7

- Pelvic brim separates abdominal & pelvic cavities
 - abdominal cavity contains most digestive organs, kidneys & ureters
 - pelvic cavity contains rectum, urinary bladder, urethra & reproductive organs

Retroperitoneal Organs

Anatomy & Physiology: The Unity of Form and Function McGraw-Hill Education; 8th Edition



Kidneys, Ureters, Adrenal Glands, most of Pancreas, Abdominal portions of Aorta and Inferior Vena Cava

Figure A.9

Intraperitoneal Organs

organs encircled by peritoneum and connected to posterior body wall by peritoneal sheets

- **dorsal mesentery – suspends intestines from posterior abdominal wall**
 - mesocolon – dorsal mesentery of large intestine
- **ventral mesentery – suspends viscera from anterior abdominal wall**
 - greater omentum – inferolateral border of stomach
 - overlies intestines - ‘fatty apron’
 - lesser omentum – superomedial border of stomach

Mesentery and Mesocolon

Anatomy & Physiology: The Unity of Form and Function McGraw-Hill Education; 8th Edition

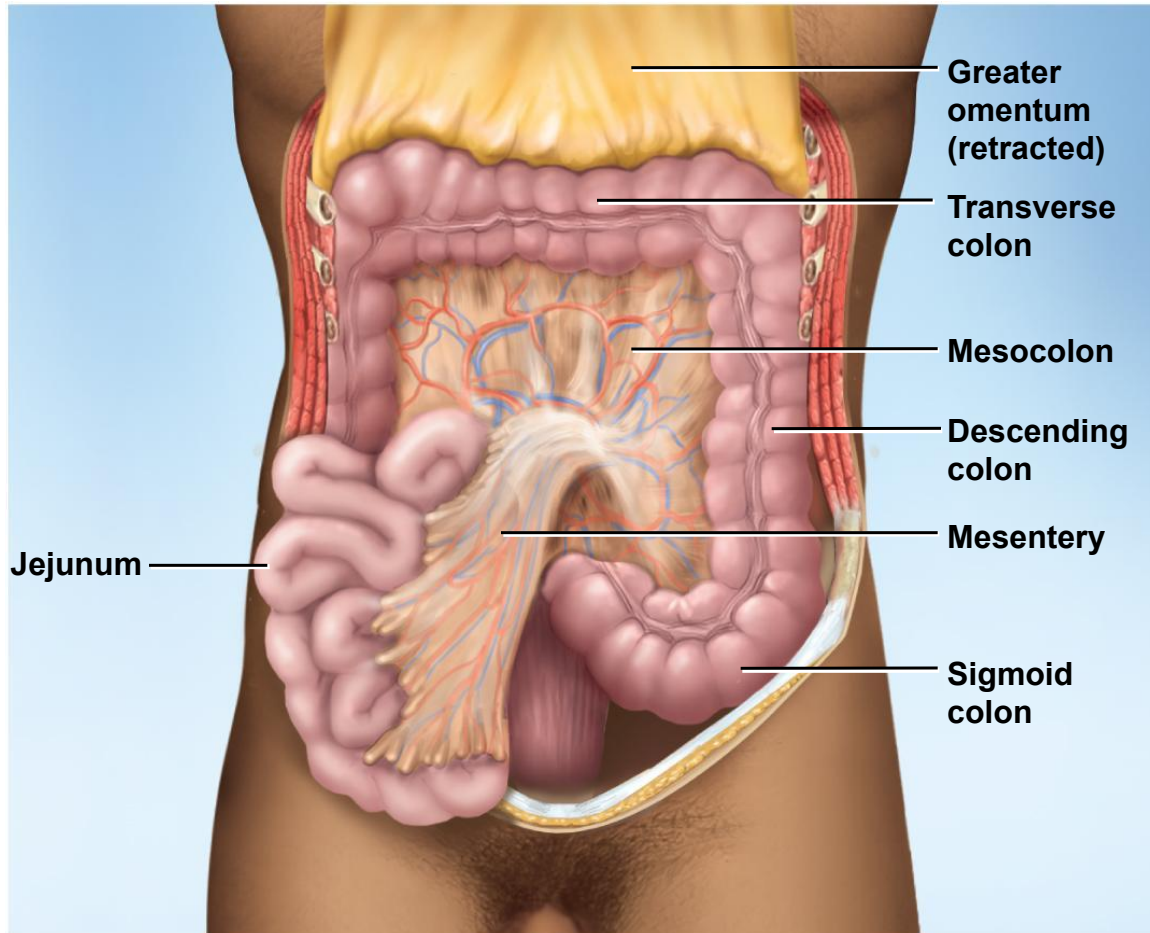


Figure 25.3b

(b)

- mesentery of small intestines holds many blood vessels
- mesocolon anchors colon to posterior body wall

Lesser and Greater Omentum

Anatomy & Physiology: The Unity of Form and Function McGraw-Hill Education; 8th Edition

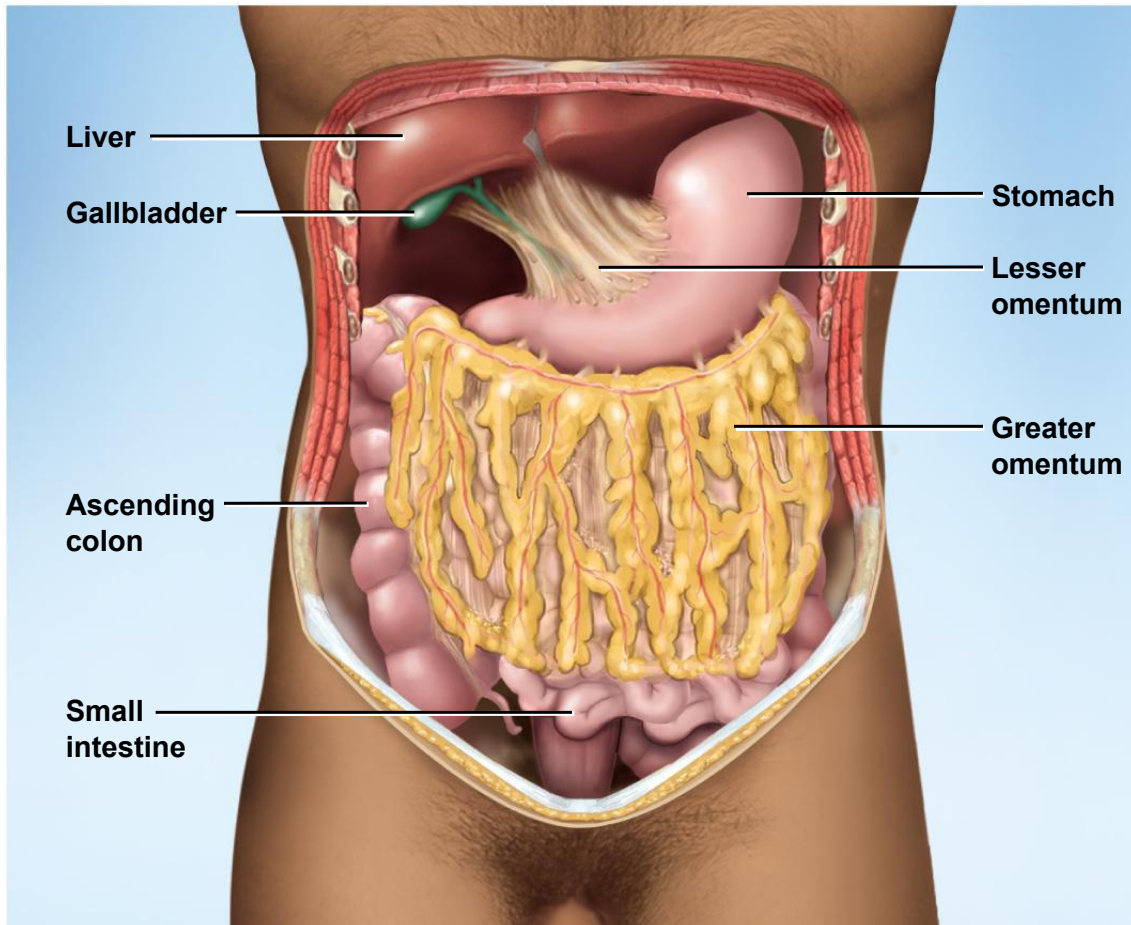


Figure 25.3a

(a)

- lesser omentum- attaches stomach to liver
- greater omentum- covers small intestines like an apron

Membranes of Abdominal Cavity

Anatomy & Physiology: The Unity of Form and Function McGraw-Hill Education; 8th Edition

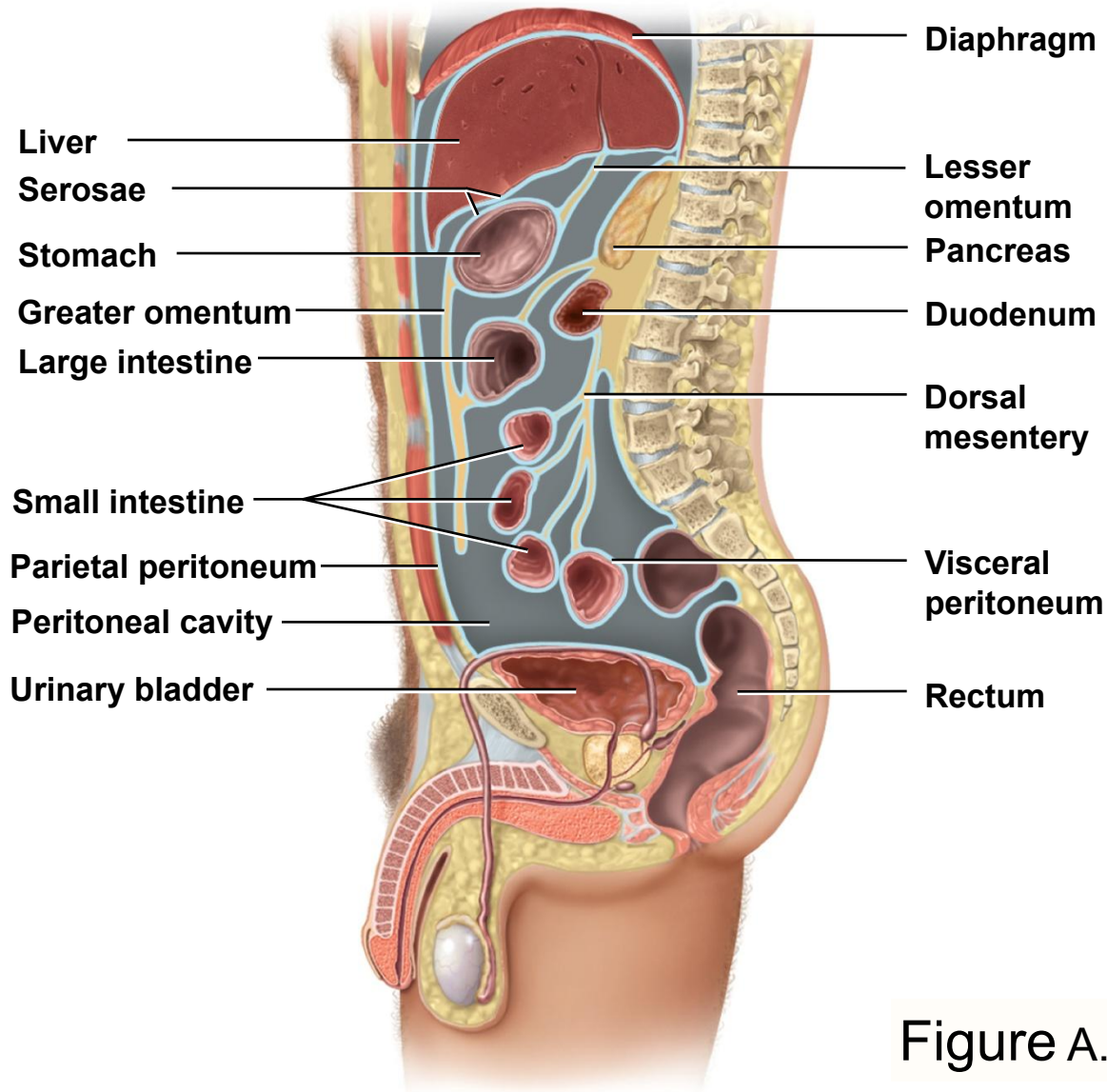


Figure A.10

Potential Spaces

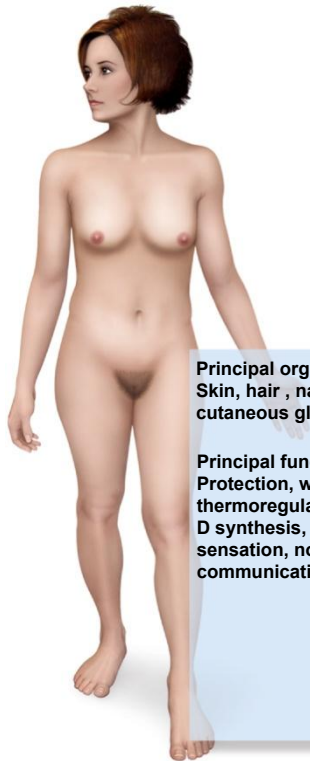
- **Found between two membranes normally pressed firmly together**
 - not physically attached, may separate, and fill with fluid in unusual situations
- **Examples**
 - **pleural cavity**
 - air or fluid can accumulate between parietal and visceral pleura forming a space
 - **uterus**
 - in a nonpregnant uterus, mucous membranes of walls are in contact

11 Organ Systems

- Protection, Support, and Movement
 - **Integumentary System**
 - **Skeletal System**
 - **Muscular System**
- Internal Communications & Integration
 - **Nervous System**
 - **Endocrine System**
- Fluid Transport
 - **Circulatory System**
 - **Lymphatic System**
- Defense
 - **Immune (Lymphatic System)**
- Input and Output
 - **Respiratory System**
 - **Urinary System**
 - **Digestive System**
- Reproduction
 - **Reproductive System**

Organ Systems (1)

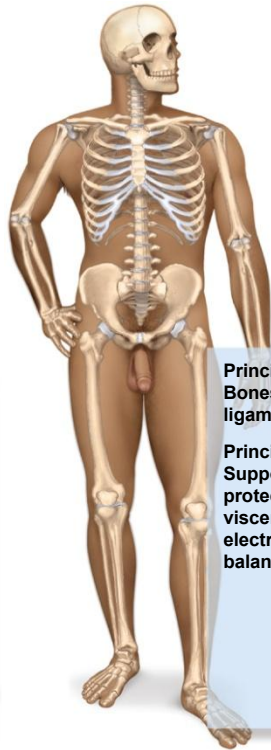
Anatomy & Physiology: The Unity of Form and Function McGraw-Hill Education; 8th Edition



Principal organs:
Skin, hair, nails,
cutaneous glands

Principal functions:
Protection, water retention,
thermoregulation, vitamin
D synthesis, cutaneous
sensation, nonverbal
communication

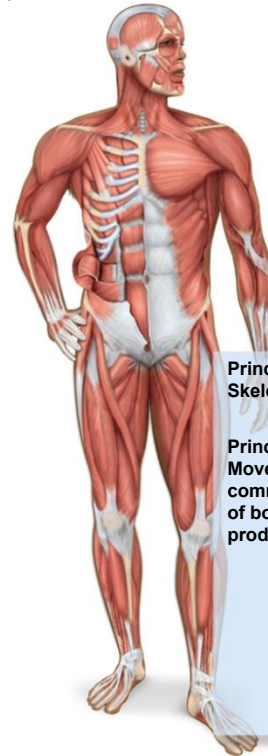
Integumentary system



Principal organs:
Bones, cartilages,
ligaments

Principal functions:
Support, movement,
protective enclosure of
viscera, blood formation,
electrolyte and acid-base
balance

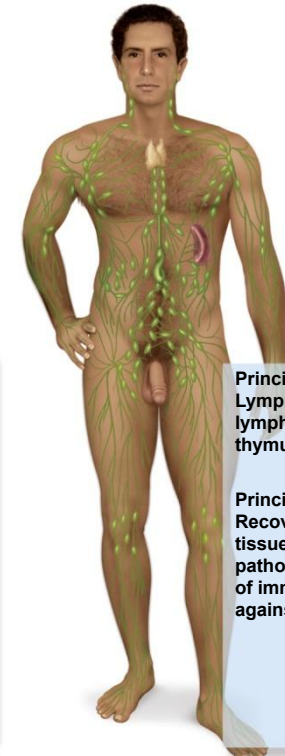
Skeletal system



Principal organs:
Skeletal muscles

Principal functions:
Movement, stability,
communication, control
of body openings, heat
production

Muscular system



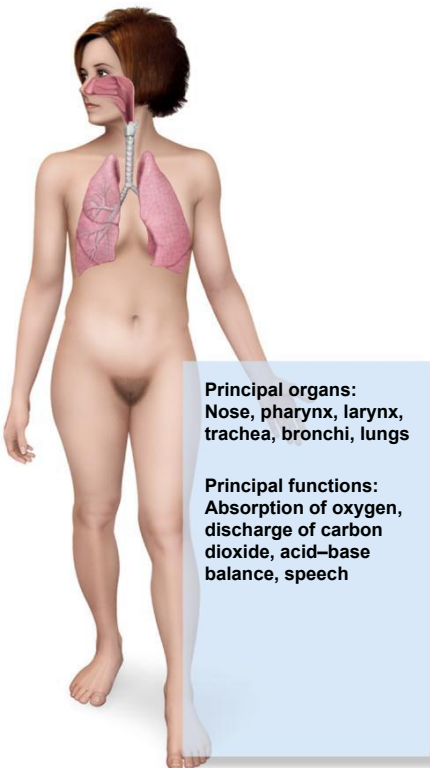
Principal organs:
Lymph nodes,
lymphatic vessels,
thymus, spleen, tonsils

Principal functions:
Recovery of excess
tissue fluid, detection of
pathogens, production
of immune cells, defense
against disease

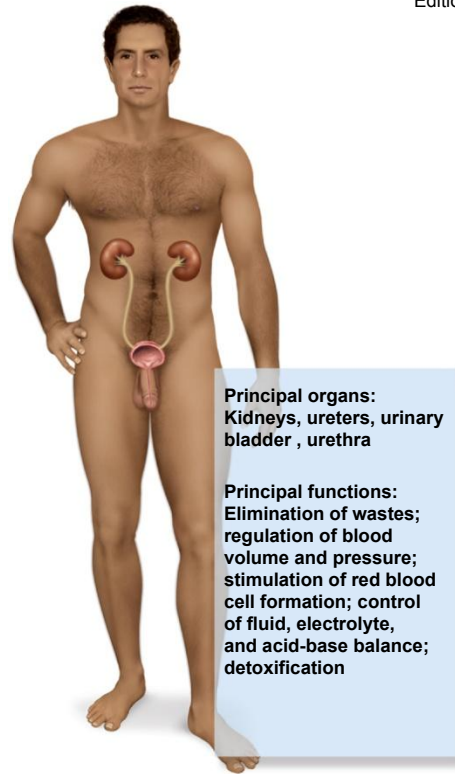
Lymphatic system

Organ Systems (2)

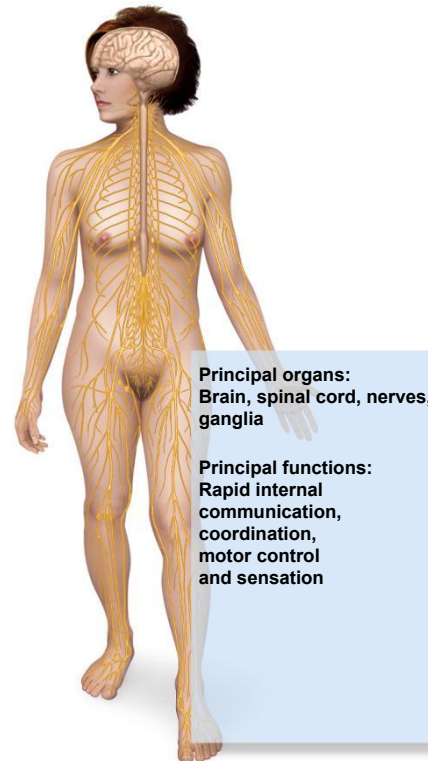
Anatomy & Physiology: The Unity of Form and Function McGraw-Hill Education; 8th Edition



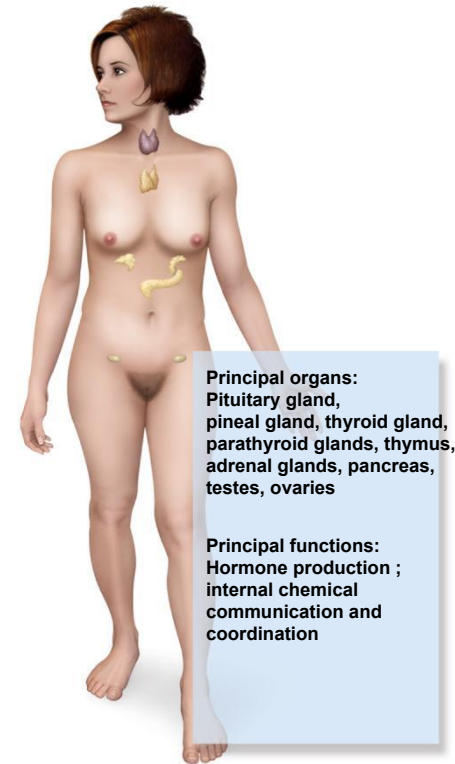
Respiratory system



Urinary system



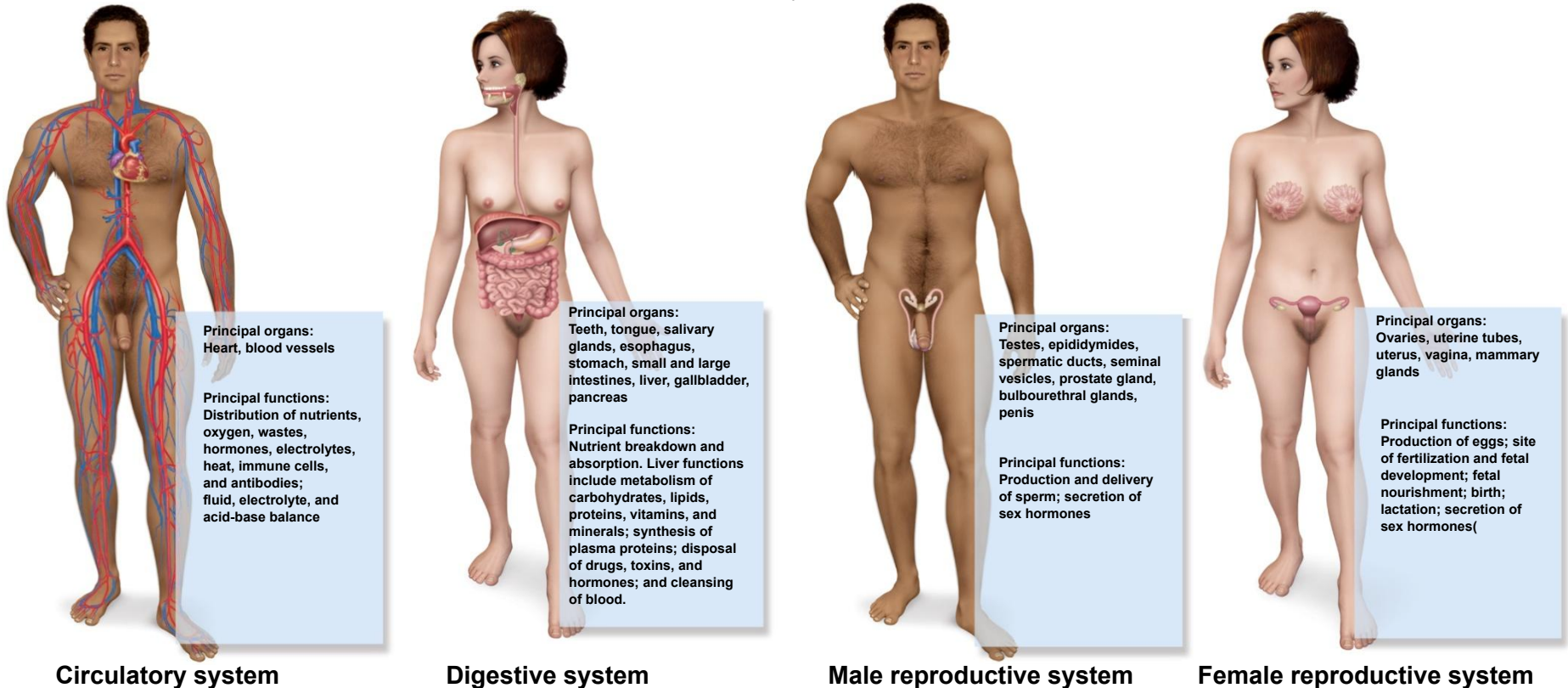
Nervous system



Endocrine system

Organ Systems (3)

Anatomy & Physiology: The Unity of Form and Function McGraw-Hill Education; 8th Edition



Principal organs:
Heart, blood vessels

Principal functions:
Distribution of nutrients, oxygen, wastes, hormones, electrolytes, heat, immune cells, and antibodies; fluid, electrolyte, and acid-base balance

Principal organs:
Teeth, tongue, salivary glands, esophagus, stomach, small and large intestines, liver, gallbladder, pancreas

Principal functions:
Nutrient breakdown and absorption. Liver functions include metabolism of carbohydrates, lipids, proteins, vitamins, and minerals; synthesis of plasma proteins; disposal of drugs, toxins, and hormones; and cleansing of blood.

Principal organs:
Testes, epididymides, spermatic ducts, seminal vesicles, prostate gland, bulbourethral glands, penis

Principal functions:
Production and delivery of sperm; secretion of sex hormones

Principal organs:
Ovaries, uterine tubes, uterus, vagina, mammary glands

Principal functions:
Production of eggs; site of fertilization and fetal development; fetal nourishment; birth; lactation; secretion of sex hormones(

Circulatory system

Digestive system

Male reproductive system

Female reproductive system

**Figure
A.11**

Superficial Anatomy (female)

Anatomy & Physiology: The Unity of Form and Function McGraw-Hill Education; 8th Edition

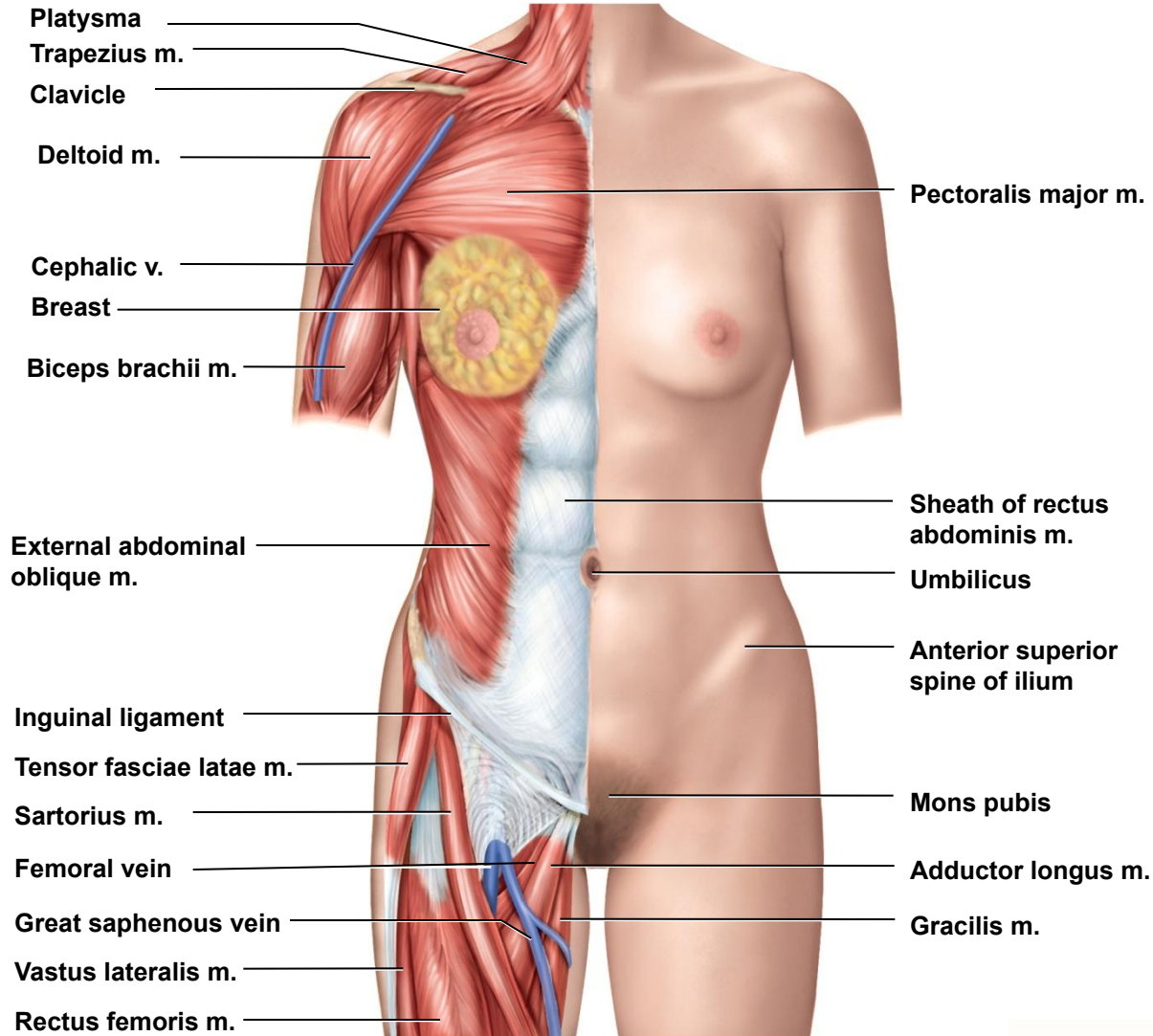


Figure A.12

Visceral Anatomy (male) 1

Anatomy & Physiology: The Unity of Form and Function McGraw-Hill Education; 8th Edition

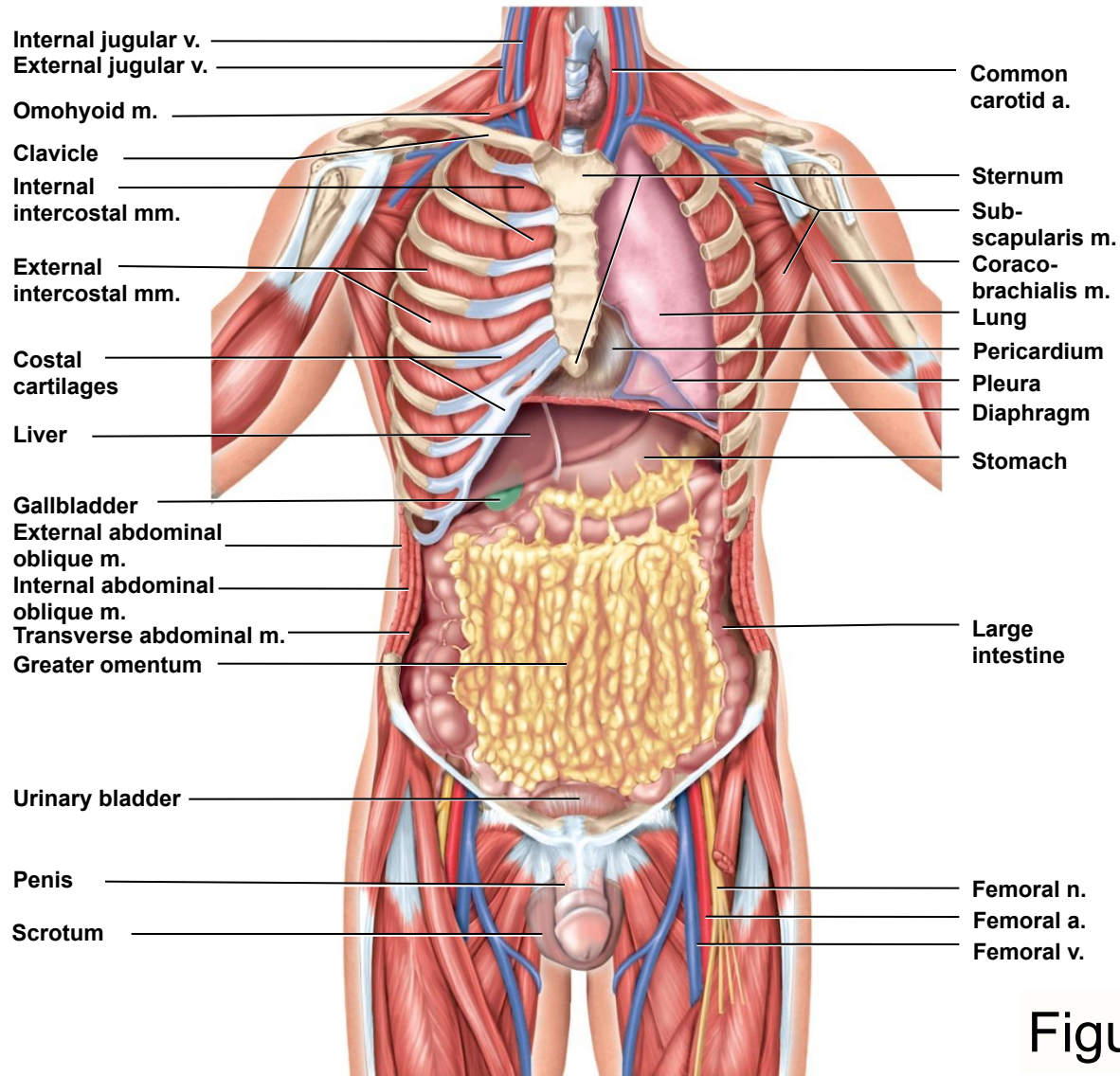


Figure A.13

Visceral Anatomy (male) 2

Anatomy & Physiology: The Unity of Form and Function McGraw-Hill Education; 8th Edition

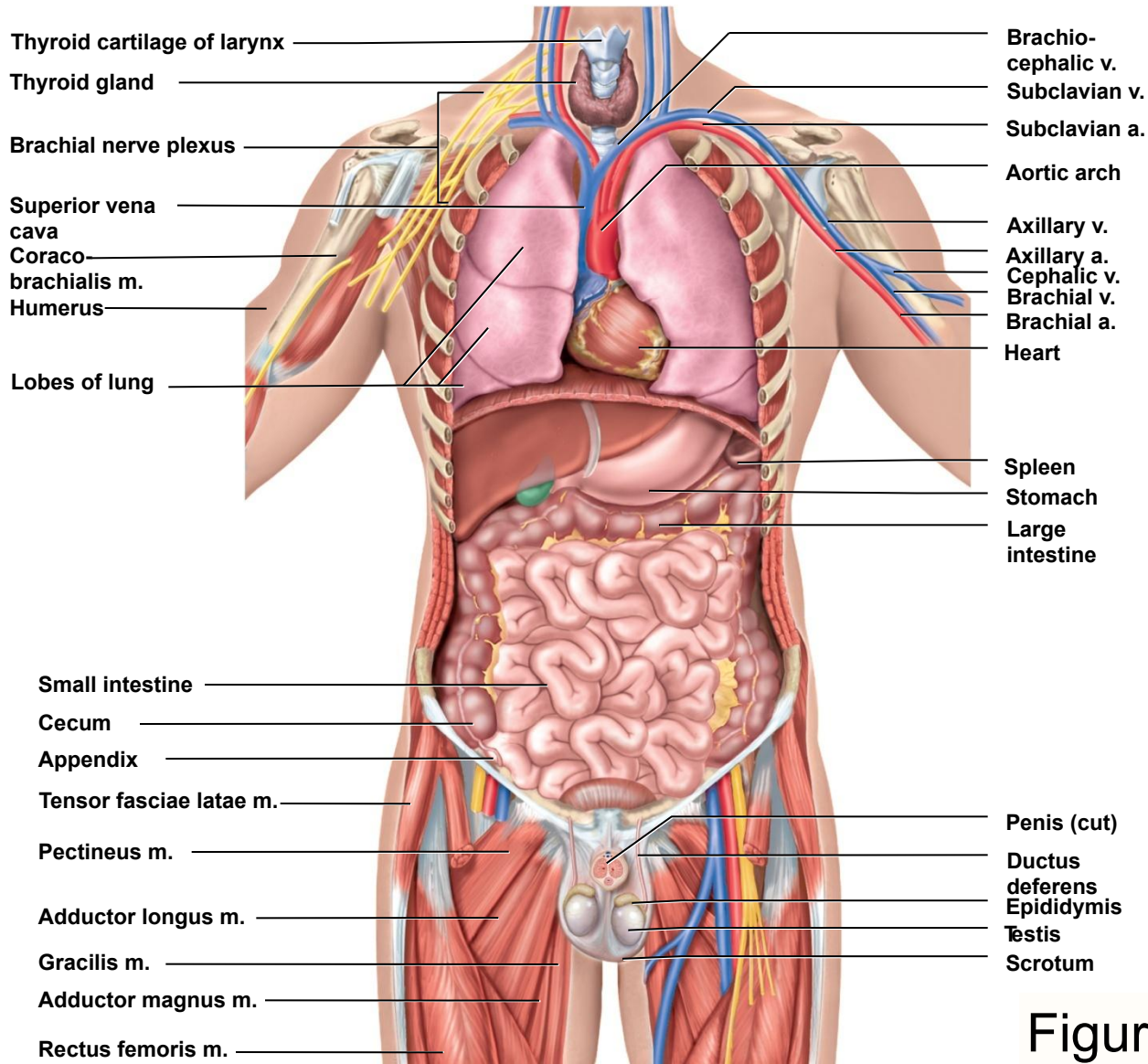


Figure A.14

Retroperitoneal Anatomy (female)

Anatomy & Physiology: The Unity of Form and Function McGraw-Hill Education; 8th Edition

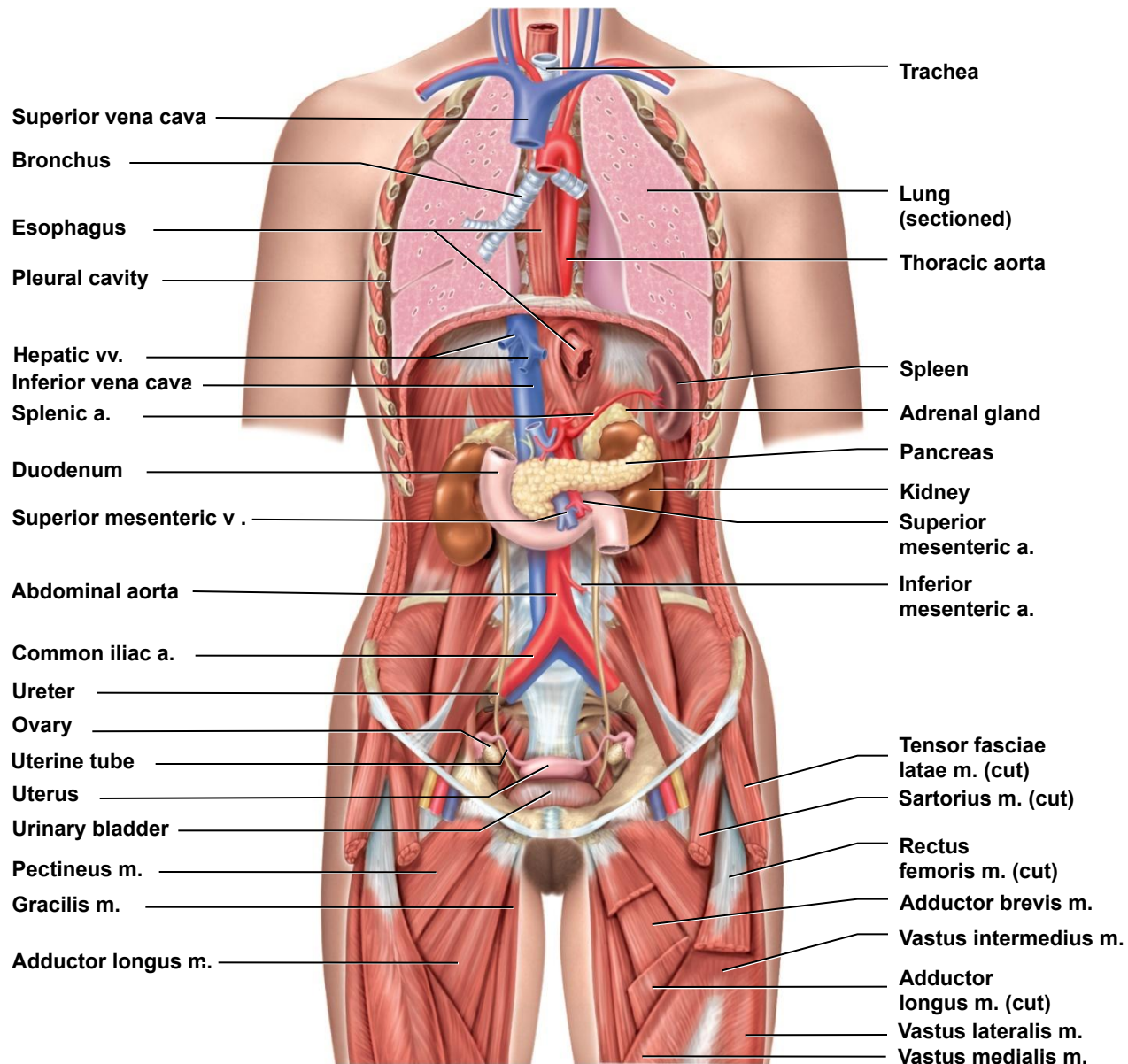


Figure A.15

Dorsal Body Wall (female)

Anatomy & Physiology: The Unity of Form and Function McGraw-Hill Education; 8th Edition

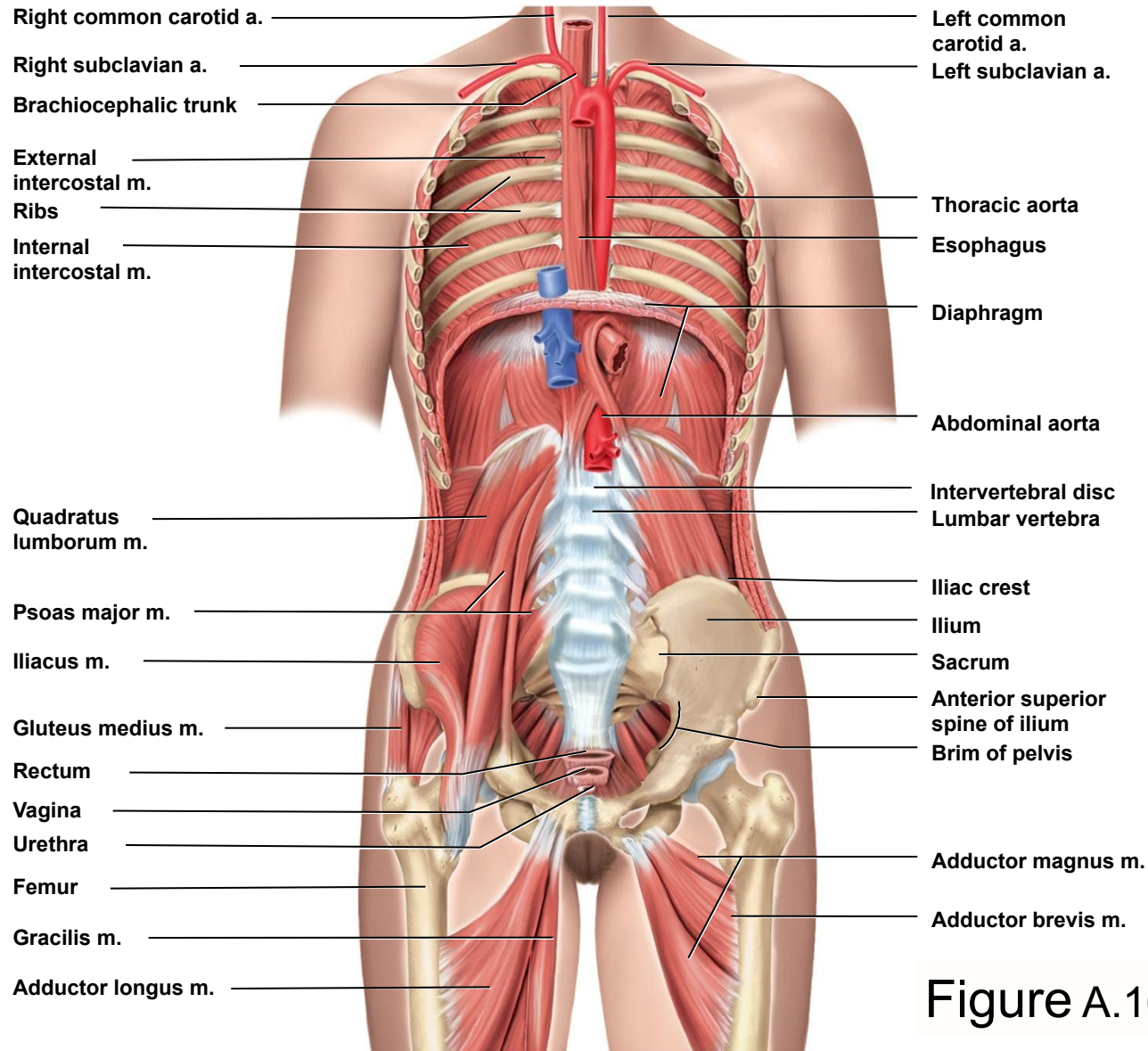


Figure A.16